

WHAT MAKES A HEART
MURMUR INNOCENT

What Makes a Heart Murmur Innocent?

IRA H. GESSNER, MD

Noting the presence of an innocent heart murmur in a child can raise a significant level of anxiety for all concerned. Improving the physician's skills in assessing this physical finding seems a worthwhile objective for several reasons in addition to accuracy of diagnosis; these include physician intellectual satisfaction, parental confidence in the physician, avoidance of stress for the patient and parents, and appropriate, cost-effective use of medical resources. This article provides both a framework and an approach to evaluating an asymptomatic heart murmur. With this information, the physician can learn how to conduct this evaluation simply, expeditiously, and accurately. Topics for discussion include mechanics of conducting a cardiac examination, specific skills necessary to evaluate a murmur, how to describe the murmur, a simplified method of murmur characterization, associated components of cardiac physical diagnosis, and assessment of accuracy in defining an innocent murmur. The term innocent, now generally accepted, conveys both meaning and a value judgment that the murmur represents a normal finding with no

EDUCATIONAL OBJECTIVES

1. Review the proper approach to cardiac examination.
2. Discuss the appropriate classification scheme for heart murmurs.
3. Review the appropriate methods for differentiating innocent from organic murmurs.

implication of a pathologic condition or process.

HOW TO APPROACH THE CARDIAC EXAMINATION

The most important, indeed essential, aspect of cardiac auscultation of the child remains familiarity with what is normal. Innocent murmurs occur in most children and in many infants; normal, therefore, includes the presence of a murmur. All physicians develop techniques that help reduce impediments to examining a young child or infant; these techniques are especially important for cardiac physical diagnosis. A struggling, crying patient precludes successful evaluation. Similarly, the environment must be pleasant and as quiet as possible. In addition, a good stethoscope should be used—one does not expect concert

continued on page 84

Dr Gessner is from the Department of Pediatrics, University of Florida, College of Medicine, Gainesville, Florida. Address reprint requests to Ira H. Gessner, MD, Dept of Pediatrics, University of Florida, College of Medicine, PO Box 100296, Gainesville, FL 32610-0296.

TABLE 1

Examiner's Skills and Traits Required for Murmur Assessment

- Understand the mechanical events of the cardiac cycle
- Knowledge of cardiac anatomy as it influences auscultation
- Motivation to accomplish a complete examination
- Awareness of murmurs as expected observation
- Confidence in acquiring information accurately

continued from page 82

hall realism when listening to music on a \$25 table radio. I recommend the Rappaport-Sprague style, particularly the model made by Hewlett-Packard.

A consistent method of examination should be developed. Comfort and ease of access to the patient is important. The patient should be supine on a comfortable table of reasonable height in such a manner that the examiner can stand to the right of the patient. If a young child or infant is not cooperative, the child should remain with the parent, perhaps lying down with his or her head on the parent's lap or leaning back against the parent. The area to be examined should be exposed; the examiner should not try to work around clothes or underwear. An appropriate gown or drape can be used for older girls and young women. The patient's general appearance and respiratory rate and pattern should be observed.

The examiner palpates pulses in both arms and in at least one leg followed by the chest and suprasternal notch. Auscultation is begun in the second right intercostal space at the sternal border. Abnormal sounds are less frequent in this aortic area, allowing the examiner to establish cardiac rate and rhythm more easily and to identify first and second heart sounds; these data represent the essential framework of auscultation without which further progress becomes impossible. Proceed then to the other auscultatory areas, listening in each first with the bell of the stethoscope and then repeating the sequence using the diaphragm.

EXAMINER'S SKILLS AND TRAITS REQUIRED FOR MURMUR ASSESSMENT (TABLE 1)

Mechanical Events of the Cardiac Cycle

Medical education includes learning the mechanical events of the cardiac cycle as depicted in Figure 1. The examiner must possess a fundamental understanding of this information to interpret what is heard during auscultation. All murmurs are generated by blood flow. Therefore, one must know at all times during the cardiac cycle where blood flows normally and what possibilities exist for pathologic flow. For example, during isovolumetric contraction (Figure 1), all four cardiac valves are closed. Blood does not

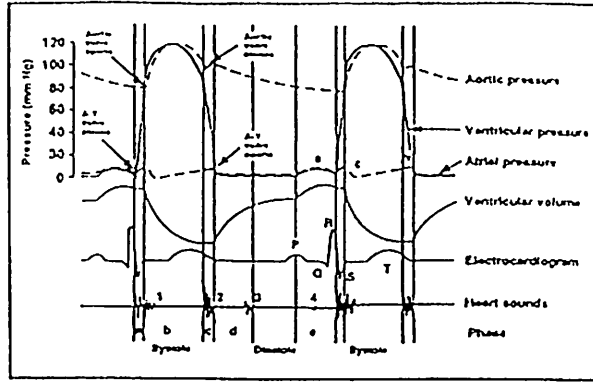


Figure 1. Mechanical events of the cardiac cycle illustrating these events in the left heart. A-V valve=mitral valve. Atrial pressure curve: a=atrial contraction, c=ventricular contraction, and v=atrial filling. Phase: a=isovolumetric contraction, b=ventricular ejection, c=isovolumetric relaxation, d=rapid ventricular filling, and e=atrial contraction. Note that a and b comprise systole and diastole includes c, d, and e. (Reprinted with permission from Gessner IH, Victorica BE, eds. *Pediatric Cardiology—A Problem-Oriented Approach*. Copyright ©1993, WB Saunders Co.)

move, and an innocent murmur cannot occur. If a murmur does occur during isovolumetric contraction, it must represent pathology. The importance of learning the general principles illustrated in Figure 1 cannot be overemphasized.

Knowledge of Cardiac Anatomy as It Influences Auscultation

It is important to keep in mind the locations of the main cardiac structures, particularly as they relate to the chest surface and the standard auscultatory areas. Figure 2 projects the ventricles and great arteries onto the chest surface, localizing acoustic events arising in these structures according to their distribution areas. The right ventricle lies in front of most of the left ventricle so that only the left ventricular apex is uncovered, hence the best listening area for left ventricular sound events is at the cardiac apex.

Motivation to Accomplish a Complete Examination

A cursory examination of the heart results in minimal information, often incomplete and sometimes incorrect. How long does it take to accomplish a cardiovascular physical examination in a cooperative, normal child? With much experience, one can do this in 1 or 2 minutes. With reasonable experience, most physicians can do this in 3 to 4 minutes. Utilization of these skills requires training, ability, desire, and a willingness to practice these skills. The examiner must know what needs to be done (and why), how to do it (and interpret it), and must want to do it well. It is analogous with playing either the piano or third base.

continued on page 87

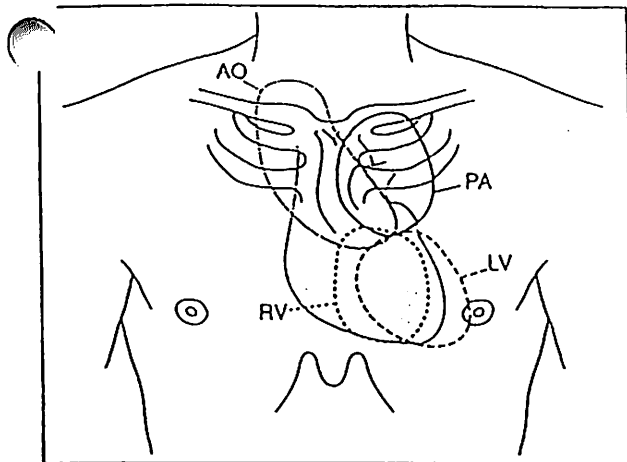


Figure 2. Projection of ventricles and great arteries onto the anterior chest wall indicating their areas of sound distribution. AO=aorta, LV=left ventricle, PA=pulmonary artery, and RV=right ventricle. (Reprinted with permission from Gessner IH, Victorica BE, eds. *Pediatric Cardiology—A Problem-Oriented Approach*. Copyright ©1993, WB Saunders Co.)

continued from page 84

Awareness of Murmurs as Expected Events

When examining the ear drum, the physician looks for various landmarks and anatomic structures and expects to see them. When listening to a child's heart, one expects to hear the first and second heart sounds, including splitting of the second heart sound. Since most children have an innocent murmur, the physician should assume this finding will occur in a normal examination. It should be evaluated just as any other observation would be and its normality confirmed. These skills are learned primarily by experience.

Confidence and Ability to Acquire Information Accurately

It is hard to be good at any technical skill if one feels insecure or inadequate. Confidence derives from knowledge and experience reinforced by repetitive success in accomplishing the task. All physicians can accomplish cardiac auscultation with sufficient skill to determine if the examination is normal. Precise analysis and identification of an abnormality may require another level of skill and experience such as one hopes is achieved by a cardiologist. In most instances, however, it is enough for the primary physician to determine normal or abnormal.

HOW TO DESCRIBE A MURMUR

Table 2 lists 10 characteristics that can be described regarding each heart murmur. At first glance, this list may seem lengthy, even intimidating. However, learning to evaluate a murmur using these characteristics generally is orderly and logical.

- **Timing.** Murmurs can be systolic, diastolic, or continuous.

TABLE 2

Murmur Descriptors
• Timing
• Location
• Intensity
• Duration
• Frequency
• Shape
• Quality
• Radiation
• Effect of respiration
• Response to interventions

- **Location.** Define the area on the chest where the murmur is the loudest.
- **Intensity.** Murmurs are graded as I through VI. Defining the loudness of a murmur is in part subjective, but if a thrill can be palpated over the murmur, it is grade IV or more. The specifics of individual grades are less important than observer consistency from one examination to another.
- **Duration.** Know how much of systole or diastole is occupied by the murmur. It is more important to note the time of onset of the murmur than how long the murmur lasts.
- **Frequency.** Frequency, or pitch, refers to a rough estimate of the dominant sound range, ie, low, middle, or high.
- **Shape.** Judge variation in intensity of the murmur. A murmur may build up (crescendo), rise and then fall (crescendo-decrescendo), decrease from a loud onset (decrescendo), or remain relatively constant (plateau).
- **Quality.** This refers to the type of noise produced by the murmur; some are noisier than others. Innocent murmurs generally are softer and more harmonic than pathologic murmurs. Terms such as harsh, coarse, blowing, etc can add meaning to the description of the murmur but generally this is of most value to the individual observer and is hard to convey accurately to others.
- **Radiation.** Murmurs spread in a predictable direction from their point of maximal intensity depending on the anatomic structures involved and murmur intensity.
- **Effects of Respiration.** Some murmurs, particularly those arising in the right heart, are altered by variation in systemic venous return due to respiration.
- **Response to Intervention.** A few simple procedures can be used during an examination. These include Valsalva, sustained hand grip exercise, and change in patient body position.

MURMUR TYPES

Continuous Murmur

With one quite rare exception, all continuous murmurs arise in blood vessels because only in blood vessels does flow continue from systole to diastole.

BLE 3

Classification of Systolic Murmurs

- Early (Onset With First Heart Sound)
 - Atrioventricular valve regurgitation
 - Ventricular septal defect
- Ejection (Onset After Isovolumetric Contraction)
 - Ventricular outflow obstruction
 - Subvalvar
 - Valvar
 - Supra-valvar
 - Innocent
 - Vibratory (Still's)
 - Pulmonary flow
 - Supraclavicular

This defines a continuous murmur, that is, one that begins in systole, continues through the second heart sound, and ends in diastole. (No murmur begins in diastole and continues through the first heart sound into systole.) The most common continuous murmur is the venous hum, an innocent murmur audible in many children placed in the sitting position. The most common pathologic continuous murmur is that caused by a ductus arteriosus.

Diastolic Murmur

It is best for the primary physician to consider all diastolic murmurs as pathologic in origin. There is one innocent diastolic murmur that remains difficult even for trained observers to detect.

Systolic Murmurs

A simplified approach to classification of systolic murmurs, presented in Table 3, can help organize what might seem to be a large number of possibilities. In fact, there are only four causes of systolic murmurs: atrioventricular valve regurgitation, ventricular septal defect, ventricular outflow tract obstruction, and innocent. All murmurs confined to systole are generated by ventricular contraction. At the beginning of systole during isovolumetric contraction all four cardiac valves are closed. Blood cannot move and no sound can occur in the normal heart. A murmur that occupies early systole, beginning exactly with the first heart sound, can be caused only by atrioventricular valve regurgitation or by a ventricular septal defect. Murmurs starting after opening of the aortic or pulmonic valve, therefore, are ejection murmurs, and all innocent systolic murmurs must be in this category (the mid-systolic murmur of mitral regurgitation due to mitral valve prolapse represents an exception to this categorization of mid-systolic murmurs as ejection).

The primary care physician is concerned with one fundamental decision: is the murmur pathologic?

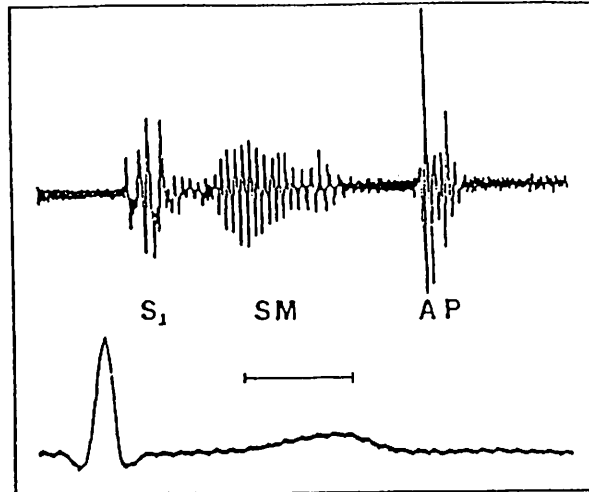


Figure 3. Phonocardiogram from a child with a vibratory (Still's) innocent murmur. Note the uniform frequency of the murmur and its biphasic shape. S₁=first heart sound, SM=systolic murmur, A=aortic component of S₂, P=pulmonic component of S₂, and horizontal line=0.1 second. (Reprinted with permission from Gessner IH, Victorica BE, eds. *Pediatric Cardiology—A Problem-Oriented Approach*. Copyright ©1993, WB Saunders Co.)

Precise diagnosis may be achieved, but accuracy in defining existence of pathology is the first priority. We now turn to specific characteristics of four common innocent murmurs according to the guidelines just described.

INNOCENT MURMURS

Innocent Systolic Murmurs

Vibratory (Still's) Murmur. In 1909, Still described the innocent, vibratory, systolic murmur that bears his name. Following the descriptors in Table 2, this murmur is mid-systolic and is best heard over the lower mid-precordium. It is seldom louder than grade II/VI, lasting perhaps one third to two thirds of systole and ending well before the second heart sound (Figure 3). Frequency may be either mid or high but remains reasonably uniform, giving it a typical harmonic character. The murmur tends to rise, fall, and then rise again before ending, thereby creating its characteristic shape. The murmur, being harmonic, demonstrates less noise than most murmurs and therefore has a soft, pleasant quality. The murmur does not radiate significantly, and because the murmur originates within the left ventricle, respiration produces no significant effect. Change in body position to sitting or standing, however, usually results in decreased intensity of the murmur. Increased heart rate, as after exercise, also reduces intensity. Most clinical investigations into the origin of this murmur indicate it comes from either turbulence in the left ventricular outflow tract or as a result of vibration of fibrous bands of tis-

continued on page 90

The most important aspect of cardiac auscultation of the child remains familiarity with what is normal.

continued from page 88

sue crossing the left ventricular lumen, now frequently identified by echocardiography.

This murmur can be distinguished from either a small ventricular septal defect or mitral regurgitation because in both of those conditions, the systolic murmur begins directly with the first heart sound. The murmur of a small ventricular septal defect is harsh and noisy, and tends to radiate toward the right sternal edge. A murmur of mitral regurgitation usually is best heard at the apex. It may have a smooth, somewhat harmonic quality, but it does not demonstrate variation in intensity. A loud vibratory innocent murmur might raise concern regarding either right or left ventricular outflow tract obstruction. However, in those pathologic conditions, the murmur generally has a coarser, noisier character, lacking the harmonic quality of the vibratory murmur. In all of the pathologic conditions just mentioned, additional clinical findings beyond the presence of a murmur helps differentiate between an innocent murmur and a pathologic murmur.

Pulmonic Flow Murmur. The pulmonic flow murmur is mid-systolic and is best heard in the second to third left intercostal space just to the left of the sternal edge. This murmur is seldom more than grade II/VI, occupying approximately two thirds of systole. Usually of mid-frequency, the murmur has a diamond shape. Its quality generally is soft but noisier than a vibratory murmur. The murmur radiates over the branch pulmonary arteries, particularly on the left, and may be audible in the axillae. The murmur tends to decrease during inspiration and also decreases when the child sits. Conditions that increase cardiac output such as fever or anemia increase intensity of the murmur. Turbulent flow, particularly at the origin of the right and left pulmonary arteries, creates this murmur.

Identifying this murmur as innocent generally is straightforward based on the criteria just mentioned, but one also must identify that the remainder of the cardiovascular examination is normal. In particular, the examiner must be certain, based on palpation of the chest, that there is no evidence of right ventricular dilation or hypertrophy, that no ejection sound over the pulmonic artery exists, that the second heart sound splits and varies normally with normal intensity of the pulmonic component, and that no diastolic murmur exists over the right ventricle at the lower left sternal border. Absence of all of these pathologic findings provides confidence that the pulmonic flow murmur is not associated with an atrial level left to right

shunt or pulmonic valve stenosis. A pulmonic flow murmur generated by mild stenosis of the pulmonary arteries cannot be distinguished from the innocent pulmonic flow murmur in all cases. If physical examination suggests evidence of right ventricular enlargement with no other findings than the pulmonic flow murmur, an electrocardiogram may prove useful.

Supraclavicular Systolic Murmur. The supraclavicular systolic murmur begins after the first heart sound and is best heard underneath the right clavicle. The murmur generally is grade II but can be grade III and usually is of short duration, occupying less than one half of systole. Murmur frequency is low and is diamond shaped with a somewhat noisy quality. The murmur radiates into the neck, particularly on the right. Respiration has no effect. The murmur intensity decreases significantly when the child sits with the shoulders hyperextended by bringing the arms behind the patient.

This murmur is caused by turbulence in the major brachiocephalic arteries as these vessels arise from the aorta. Differential diagnosis of this murmur seldom presents a problem. The murmur of aortic valve stenosis may come to mind, but can easily be distinguished by its specific characteristics as well as the presence of an aortic ejection sound.

Innocent Continuous Murmur

The only innocent continuous murmur is a venous hum. This murmur begins shortly after the first heart sound and is located just beneath the right sternoclavicular junction with the patient sitting. The murmur is grade II/VI or less. The murmur begins just after the first heart sound and lasts throughout all of systole and approximately two thirds of diastole. Of medium frequency, the murmur has a characteristic shape rising to a peak during systole, decreasing in late systole and then increasing again to a louder peak in early to mid-diastole as the tricuspid valve opens. The murmur is soft and does not radiate. The murmur may decrease slightly during inspiration although this seldom is noticeable. The diastolic component of the murmur can be obliterated by compression of the right jugular veins. The murmur also disappears when the patient is supine.

This murmur is caused by turbulence in the major veins entering the thoracic inlet and is augmented by gravity when the patient sits. The highly compliant right ventricle of a child allows rapid flow from these veins into the right heart. Although one may confuse this murmur with that of a patent ductus arteriosus, differentiation seldom is difficult if appropriate examination is carried out. The diastolic component of the venous hum, as mentioned, can be obliterated easily whereas the murmur of a ductus arteriosus cannot be manipulated in this fashion. A ductus murmur characteristically is louder and noisier, and exhibits a single peak at the second sound.

Accuracy of Physical Examination in Identifying Innocence of a Heart Murmur

Several studies attest to the ability of experienced examiners to identify a murmur as innocent without the use of additional laboratory tests. Most of these studies involve examination by a pediatric cardiologist, but results of examination by primary care physicians indicate they can be successful in this endeavor as well. The primary care physician ought not hesitate to obtain an electrocardiogram if a murmur seems unusual. Echocardiography, on the other hand, ought not be performed for screening purposes and should be ordered only by a physician who has clearly identified a specific diagnostic problem to be resolved by this significantly more expensive procedure. Proper assessment of an innocent murmur by the primary care physician benefits everyone. The patient and parents are reassured without delay, the analysis is intellectually satisfying to the physician accomplishing it, and the process is cost effective.

TOTAL CARDIAC EXAMINATION

Evaluation of a heart murmur does not occur in isolation from the remainder of the cardiac physical examination. The murmur must be evaluated in association with the company that it keeps. This presentation cannot review the remainder of the cardiovascular physical examination. The physician must be able to evaluate arterial pulses, chest wall movements, heart sounds, ejection sounds, clicks, and rubs.

SUMMARY

The physician determines that a murmur is innocent by evaluating it on its own merits. The information should be assessed in a logical and orderly fashion,

and the possibilities are considered based on the information that is obtained. All of this information is processed through the physician's knowledge and experience base, and then a decision is made. One cannot increase one's skill as a cardiac auscultator by reading articles such as this—one can only learn what is abnormal by being completely comfortable with what is normal. There is no substitution for listening to many hearts, but the physician must listen to normal hearts thoughtfully and analytically. What makes a heart murmur innocent? The answer to this question includes the characteristics of the murmur in the context of the patient's total cardiovascular examination. How are these characteristics determined? They are determined the same way as any other technical skill is accomplished—with practice.

BIBLIOGRAPHY

- Danford DA, Nasir A, Gumbiner C. Cost assessment of the evaluation of heart murmur in children. *Pediatrics*. 1993;91:365-368.
- Darazi B, Hesdorffer CS, Buttenworth AM, Ziad F. The possible etiology of the vibratory systolic murmur. *Clin Cardiol*. 1987;10:341-346.
- Gesner IH. Evaluation of the infant and child with a heart murmur. In: Gesner IH, Victoria BE, eds. *Pediatric Cardiology—A Problem-Oriented Approach*. Philadelphia, Pa: WB Saunders Co; 1993:131-146.
- Gesner IH. Physical examination. In: Gesner IH, Victoria BE, eds. *Pediatric Cardiology—A Problem-Oriented Approach*. Philadelphia, Pa: WB Saunders Co; 1993:3-22.
- Hansen LK, Birkebaek NH, Oshoj H. Initial evaluation of children with heart murmurs by the non-specialized pediatrician. *Eur J Pediatr*. 1993;154:15-17.
- Klewer SE, Donnerstein RL, Goldberg SJ. Still's-like innocent murmur can be produced by increasing aortic velocity to a threshold value. *Am J Cardiol*. 1991;68:810-812.
- Newburger JW, Rosenthal A, Williams RG, Fellows K, Miettinen OS. Noninvasive tests in the initial evaluation of heart murmurs in children. *N Engl J Med*. 1983;308:61-64.
- Smythe JF, Teixeira OHR, Vlad P, Demers PP, Feldman W. Initial evaluation of heart murmurs: are laboratory tests necessary? *Pediatrics*. 1990;86:497-500.
- Still G. *Common Disorders and Diseases of Childhood*. London, England: Frowde, Hodder & Stoughton; 1909.
- Van Oort A, Le Blanc-Borden M, De Boo T, Van Der Werf T, Rohmer J, Daniels O. The vibratory innocent heart murmur in schoolchildren: difference in auscultatory findings between school medical officers and a pediatric cardiologist. *Pediatr Cardiol*. 1994;15:232-237.
- Zonerich S, Spodick DH. Bedside science reduces laboratory art. *Circulation*. 1993;91:2089-2092.